Case Report
The Korean Journal of Pancreas and Biliary Tract 2016;21:112-116
http://dx.doi.org/10.15279/kpba.2016.21.2.112

pISSN 1976-3573 eISSN 2288-0941

십이지장 구부에 담관의 이소성 개구를 가진 환자에서 위내시경을 이용한 내시경 역행성 담췌관 조영술과 직접 담도조영술: 3개의 증례

을지대학교 의과대학 을지대학병원 소화기내과
장지웅 · 김새희 · 정성희 · 김안나

ERCP and Direct Cholangioscopy with Gastroscope in Patients with Ectopic Opening of the Bile Duct into the Duodenal Bulb: A Report of 3 Cases

Ji Woong Jang, Sae Hee Kim, Sung Hee Jung, Anna Kim

Division of Gastroenterology, Department of Internal Medicine, Eulji University Hospital, Eulji University College of Medicine, Daejeon, Korea

Ectopic openings of the common bile duct into the duodenal bulb, which are associated with biliary tract disease or recurrent/refractory duodenal ulcers, are rare. We report three such cases, all of which were documented with gastroscope, and two of which were managed with endoscopic retrograde cholangiopancreatography (ERCP) via gastroscope. We suggest that ERCP can be performed with gastroscope, since it may offer a better working position in certain cases.

Korean J Pancreatobiliary 2016;21(2):112-116

Received Oct. 5, 2015
Revised Oct. 28, 2015
Accepted Nov. 16, 2015

Corresponding author : Ji Woong Jang
Division of Gastroenterology, Department of Internal Medicine, Eulji University Hospital, Eulji University College of Medicine, 95 Dunsanseo-ro, Seo-gu, Daejeon 35233, Korea
Tel. +82-42-611-3063 Fax. +82-42-259-1211
E-mail; jj98w@naver.com

Keywords: Ectopic opening, Common bile duct, Duodenal bulb, ERCP

INTRODUCTION

The common bile duct (CBD) typically enters the posteromedial aspect of the second portion of the duodenum.[1] It can open at anomalous sites, including the third or fourth portions of the duodenum, the antrum of the stomach, or the duodenal bulb.[2-6] In most cases, the CBD opens in the third or fourth portions of the duodenum; ectopic openings of the CBD into the duodenal bulb are very rare.[1,3,7-10] Although there have been a few series that investigated ectopic openings of the CBD, cases documented with gastroscope are little-known.[11] Therefore, we report on three cases of ectopic openings of the CBD into the duodenal bulb, all documented via gastroscope.

CASE

Case 1

A 55-year-old male complained of upper abdominal pain and fever. His past history revealed duodenal ulcer bleeding, which had been managed endoscopically and medically 15 years earlier. On admission, his physical examination revealed tenderness in the upper abdomen, and laboratory tests of the serum showed the following levels: white blood cell (WBC) count, 15,810/uL; C-reactive protein (CRP), 3.83 mg/dL; aspartate aminotransferase (AST), 548 IU/L; alanine transaminase (ALT), 498 IU/L; alkaline phosphatase (ALP), 251 IU/L; gamma-glutamyl transpeptidase (GGT), 502 IU/L; and total bilirubin, 3.26 mg/dL.

Abdominal computed tomography (CT) showed dilatation of the CBD with suspected choledocholithiasis and pneumobilia. Endoscopic retrograde cholangiopancreatography (ERCP) was attempted, but the papilla of Vater was not identified in the second portion of the duodenum and severe duodenal deformity was present, resulting in a difficult procedure. Emergent percutaneous transhepatic biliary drainage (PTBD) was performed due to progressive cholangitis. Cholangiogram via a PTBD catheter showed bile duct dilatation with multiple small stones, and slightly proximally located opening of the CBD was suspected. CBD stones were removed antegradely via the PTBD tract after the infection had improved. An angulated bile duct was observed on follow-up cholangiogram after stone removal (Fig. 1A). The patient underwent gastroscopy (Olympus GIF-H-260, Olympus Optical, Tokyo, Japan) for confirmation of the papilla of Vater, with contrast filling the CBD via a PTBD catheter (Fig. 1B). A slit-like opening was located, from which bile flowed into the duodenal bulb (Fig. 2A). When the scope was pushed into the opening after dilatation of the papilla with a balloon catheter (CRE wire-guided balloon dilator; Boston Scientific, MA, USA), a previously inserted PTBD catheter with an orifice into the intrahepatic duct was observed (Fig. 1C, 2B). The patient was discharged after removal of the PTBD catheter.

Case 2

A 32-year-old man visited the emergency room because of epigastric pain and fever. He had been treated with medication for a duodenal ulcer 10 years previously. Laboratory tests of the serum revealed a WBC count of 11,360/uL, CRP of 0.52 mg/dL, AST of 246 IU/L, ALT of 239 IU/L, ALP of 110 IU/L, GGT of 171 IU/L, and total bilirubin of 1.61 mg/dL. An abdominal CT scan showed CBD stones and a dilated bile duct. ERCP was performed with duodenoscope, but failed due to severe duodenal stricture. On gastroscopy, a

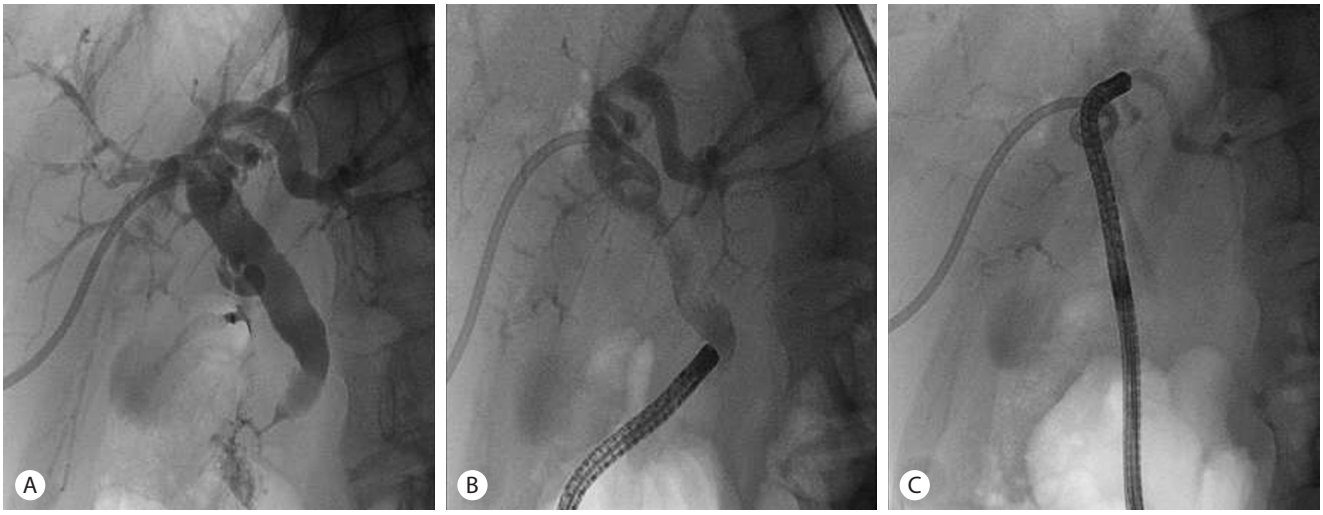

Fig. 1. (A) An angulated bile duct was observed on follow-up cholangiogram after stone removal. (B) PTBD catheter and bile duct were revealed by injection of contrast medium into the CBD via ectopic opening. (C) Fluoroscopy showed the pushed scope at the orifice of the left intrahepatic duct. PTBD, percutaneous transhepatic biliary drainage; CBD, common bile duct.

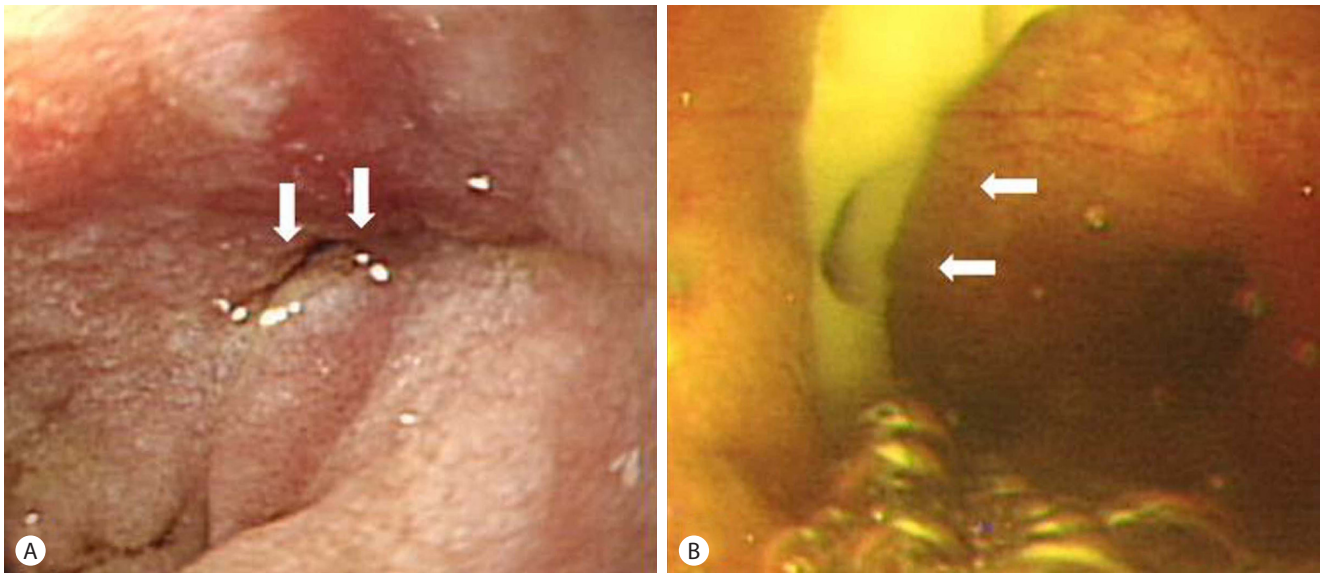

Fig. 2. (A) Gastroscopy showed a bile-stained, slit-like, ectopic opening (arrows). (B) Previously inserted PTBD catheter (arrows) and orifice into the intrahepatic duct were observed when the scope was pushed into the CBD. PTBD, percutaneous transhepatic biliary drainage; CBD, common bile duct.

Fig. 3. An ectopic opening with removed muddy stones after balloon dilatation and balloon sweeping was noted during ERCP with gastroscope. ERCP, endoscopic retrograde cholangiopancreatography.

slit-like opening was identified in the duodenal bulb, and ERCP was successfully performed with the gastroscope via cannulation of the ectopic opening in the duodenal bulb. The patient underwent dilatation of the papilla with a balloon catheter, and a basket was used to remove the stones (Fig. 3). The scope was pushed into the CBD after stone removal, and the internal wall of the bile duct and several orifices into the branch duct were noted. The patient was discharged without complications.

Case 3

A 60-year-old man was referred to the hospital for right upper quadrant abdominal pain and fever. He had undergone cholecystectomy five years earlier and had been diagnosed with a duodenal ulcer two years earlier. Physical examination on admission revealed tenderness in the right upper quadrant of the abdomen, and laboratory studies showed leukocytosis, elevated liver enzymes, and hyperbilirubinemia. CBD stones with bile duct dilatation were noted on an abdominal CT scan. ERCP was performed, and the papilla was not observed in the normal location; indeed, a slit-like opening was located in the deformed bulb of the duodenum just before a partial apical stricture. Due to the deformities in this region, positioning with a side-viewing duodenoscope was not possible for intervention, so a conventional gastroscope was inserted. The bile duct was cannulated, the papilla was dilated with a dilatation balloon, and stones and sludge were removed. The patient was discharged without any complications.

DISCUSSION

Reports on the ectopic opening of the CBD in the duodenal bulb are rare, including few Korean reports,[8-10] although

 http://dx.doi.org/10.15279/kpba.2016.21.2.112

the overall frequency of various ectopic openings of the CBD is known to be 5.6-23%.[12] The exact prevalence is not known because the percentage of asymptomatic individuals cannot be determined in the absence of a consistent autopsy study. Nevertheless, the true incidence could be much higher than presently appreciated, as Lee at al.[1] stressed recently.

The cause of anomalous drainage of the CBD has been ascribed to unidentified errors in embryogenesis.[6] Briefly, ectopic bile duct drainage occurs because of disproportional elongation and early subdivision of the primitive hepatic furrow as it develops from the pars hepatica and pars cystica.[1,6]

An ectopic opening of the CBD into the duodenal bulb is not an incidental finding; it is a pathologic condition that can be associated with clinical entities such as biliary tract disease or recurrent/intractable duodenal ulcers. It is commonly associated with biliary disease.[1,4,13,14] In all three of our patients, choledocholithiasis with cholangitis was observed. One adequate explanation for this is that the hook-shaped configuration of the distal CBD, which may result from an acute angulation of the CBD, causes defective drainage of bile, which may be associated with bile stasis. This configuration should be considered a characteristic finding for the anomaly of an ectopic opening of the CBD into the duodenal bulb, especially in the absence of any prior abdominal surgery.[1] Also, in our study, the typical configuration of the major duodenal papilla was absent in all three patients, while a slit-like orifice was present on the endoscopic examination. This deformed configuration of the ectopic opening may reflect a poorly developed sphincter of Oddi, or its absence.[14] Malfunction of the valve mechanism in the distal CBD permits the influx of intestinal bacteria and gastric contents into the biliary system, which can cause transient obstructions, recurrent cholangitis, or liver abscesses.[3,13]

Unexpectedly, a history of duodenal ulcers with or without deformity was found in each of our three cases. Lee et al.[13] described duodenal deformation in five out of eight patients and active duodenal ulcers in a single patient. Lee et al.[1] also reported 13 patients with active duodenal ulcers, nine of whom had duodenal deformities, out of a total of 18 cases. These findings suggest that peptic ulcer disease may be associated with ectopic opening of the CBD into the duodenal bulb, but the cause of peptic ulcer disease in these patients is not clearly known. In contrast, fistulas secondary to ulcers or to choledocholithiasis, spontaneous or iatrogenic surgical fistulas, and surgical choledochoenteric diversion should be included in the differential diagnosis.[15] Non-visualization of the major papilla in the second portion of the duodenum may be the key to ruling out these conditions. If ectopic opening of the CBD is overlooked at surgery for intractable peptic ulcer disease, serious injury to the bile duct may occur. In addition, recurrent duodenal ulcer related with this may induce mucosal swelling and fibrosis with occlusion of the ectopic orifice and worsening of biliary symptoms.

Although ERCP is the "gold standard" for diagnosing an ectopic opening and managing biliary problems associated with it, an ectopic opening in the duodenal bulb increases the difficulty in performing therapeutic interventions during ERCP. This has a high risk of perforation and bleeding during endoscopic sphincterotomy because the intramural portion of the duct is not fully developed.[12] Therefore, endoscopic balloon dilatation may be preferred. However, appropriate placement of a balloon catheter through an ectopic opening is very difficult, due to acute angulation of the distal CBD. In addition, as deformity and stenosis in the bulb can be as high as 49% in these patients, cannulation of the CBD may be impossible because of poor scope position.[12] Therefore, in some patients who have acute angulation of CBD and/or severe duodenal deformity, resulting in difficult procedure with duodenoscope, we recommend that the procedure is performed with a gastroscope, as shown in our two cases and previous report,[11] which may supply a better working position.

Most patients with this anomaly have biliary tract disease or a recurrent/refractory duodenal ulcer; thus, surgical treatments such as bypass surgery may eventually be necessary because of stricture of the ectopic opening and severe deformity of the duodenal bulb. Further studies are needed for

long-term outcomes in the large numbers of patients with ectopic opening in the duodenal bulb.

In conclusion, ectopic openings of the CBD into the duodenal bulb should be considered in patients with biliary tract disease or recurrent/intractable duodenal ulcers when the papilla of Vater cannot be found in the second portion of the duodenum. In addition, we suggest that the procedure is performed with gastroscope, which offer a better working position in some cases.

요 약

십이지장 구부로의 총담관의 이소성 개구는 매우 드물며, 담도 질환이나 재발성/불응성 십이지장 궤양과 관련이 있는 경우가 많다. 저자들은 직시경으로 확인하고 일부는 직시경을 이용한 내시경 역행성 담췌관 조영술로 동반된 담관염을 치료했던 3명의 환자들을 보고한다. 일부 환자에서는 직시경이 시술에 있어 더 효과적이고 유리한 시술환경을 제공할 수 있다.

국문 색인: 이소성 개구, 총담관, 십이지장 구부, 내시경 역행성 담췌관 조영술

Conflicts of Interest

The author has no conflicts to disclose.

REFERENCES

1. Lee SS, Kim MH, Lee SK, et al. Ectopic opening of the common bile duct in the duodenal bulb: clinical implications. Gastrointest Endosc 2003;57:679-682.
2. Kanematsu M, Imaeda T, Seki M, et al. Accessory bile duct draining into the stomach: case report and review. Gastrointest Radiol 1992;17:27-30.
3. Kubota T, Fujioka T, Honda S, et al. The papilla of Vater emptying into the duodenal bulb. Report of two cases. Jpn J Med 1988;27:79-82.
4. Doty J, Hassall E, Fonkalsrud EW. Anomalous drainage of the common bile duct into the fourth portion of the duodenum. Clinical sequelae. Arch Surg 1985;120:1077-1079.
5. Keddie NC, Taylor AW, Sykes PA. The termination of the common bile duct. Br J Surg 1974;61:623-625.
6. Sezgin O, Altintas E, Ucbilek E. Ectopic opening of the common bile duct into various sites of the upper digestive tract: a case series. Gastrointest Endosc 2010;72:198-203.
7. Krstic M, Stimec B, Krstic R, et al. EUS diagnosis of ectopic opening of the common bile duct in the duodenal bulb: a case report. World J Gastroenterol 2005;11:5068-5071.
8. Jeong JH LT, Yang SW, et al. A case of ectopic opening of the common bile duct associated with hematemesis. Korean J Med 2008;75:685-688.
9. Lee SS KH, Baik DS, et al. . An ectopic opening of the common bile duct ino the duodenal bulb: the clinical features and endoscopic treatment. Korean J Gastrointest Endosc 2010;40:16-21.
10. Lee JM, Kim HJ, Ha CY, et al. Ectopic Opening of the Common Bile Duct into the Duodenal Bulb Accompanied with Cholangitis and Gallbladder Cancer: A Report of Two Cases. Clin Endosc 2015;48:260-264.
11. Uskudar O, Altinbas A, Simsek Z. Endoscopic retrograde cholangiopancreatography with a gastroscope in a case of ectopic opening of common bile duct. Dig Endosc 2012;24:54.
12. Disibeyaz S, Parlak E, Cicek B, et al. Anomalous opening of the common bile duct into the duodenal bulb: endoscopic treatment. BMC Gastroenterol 2007;7:26.
13. Lee HJ, Ha HK, Kim MH, et al. ERCP and CT findings of ectopic drainage of the common bile duct into the duodenal bulb. AJR Am J Roentgenol 1997;169:517-520.
14. Ozaslan E, Saritas U, Tatar G, et al. Ectopic drainage of the common bile duct into the duodenal bulb: report of two cases. Endoscopy 2003;35:545.
15. Pereira-Lima J, Pereira-Lima LM, Nestrowski M, et al. Anomalaous location of the papilla of vater. Am J Surg 1974;128:71-74.