Case Report
The Korean Journal of Pancreas and Biliary Tract 2022;27:128-134
https://doi.org/10.15279/kpba.2022.27.3.128
pISSN 1976-3573 eISSN 2288-0941

고식적 풍선 확장에 불응성인 양성 담관 문합 협착이 있는 환자에서 구조요법으로 절단 풍선 확장

[1]부산대학교 의과대학 내과학교실, [2]부산대학교병원 의생명연구원
이종현[1,2] · 김동욱[1,2] · 한성용[1] · 김광하[1] · 서형일[1] · 홍승백[1] · 김 석[1] · 김창원[1]

Use of a Cutting Balloon Dilation as a Rescue Therapy in Patients with Benign Bilioenteric Anastomotic Strictures Refractory to Conventional Balloon Dilation

Jong Hyun Lee[1,2], Dong Uk Kim[1,2], Sung Yong Han[1], Gwang Ha Kim[1], Hyung Il Seo[1], Seung Baek Hong[1], Suk Kim[1], Chang Won Kim[1]

[1]Department of Internal Medicine, Pusan National University School of Medicine, Busan; [2]Biomedical Research Institute, Pusan National University Hospital, Busan, Korea

Percutaneous balloon dilation with or without placement of an external biliary drain is a nonoperative alternative method for treating benign bilioenteric anastomotic strictures. Although this procedure has a high technical success rate, outcomes are less optimal when attempting to dilate refractory tight strictures. For the stricture, cutting balloon can be an option. We present four patients with benign bilioenteric anastomotic strictures refractory to conventional balloon dilation. To the patients, a peripheral cutting balloon over-the-wire system was inflated, following subsequent conventional non-compliant balloon dilation. After the balloon dilation treatment, an external drainage catheter was placed through the stricture site and maintained for up to 30 days. Technical and end-treatment success was achieved in all four patients. In conclusion, the use of cutting balloon dilation may appear to be a safe and effective alternative method of treatment in patients with benign bilioenteric anastomotic strictures refractory to conventional balloon dilation.

Korean J Pancreas Biliary Tract 2022;27(3):128-134

Keywords: Cutting balloon; Bilioenteric anastomosis; Benign stricture; Percutaneous balloon dilation

Received Apr. 18, 2022
Revised Jul. 29, 2022
Accepted Jul. 29, 2022

Corresponding author : Dong Uk Kim
Department of Internal Medicine, Pusan National University School of Medicine, 179 Gudeok-ro, Seo-gu, Busan 49241, Korea
Tel. +82-51-240-7869 Fax. +82-51-254-3237
E-mail; amlm3@hanmail.net
ORCID: https://orcid.org/0000-0002-7208-7753

INTRODUCTION

Postoperative biliary stricture is a clinically significant problem that can result in complications such as cholestasis, ductal stones, recurrent cholangitis, or secondary biliary cirrhosis. Traditionally, the preferred treatment was surgery. However, surgical treatment is limited by technical difficulties and high rates of morbidity and mortality in postoperative patients, especially those with bilioenteric anastomosis.[1,2] Therefore, endoscopic or percutaneous approaches using balloon dilation have been used increasingly as alternative

treatment modalities. These treatments are less invasive and have similar long-term outcomes compared with surgery.[3,4] Even though, traditional balloon dilation treatments are sometimes not satisfactory in cases with severe fibrosis around strictures. In these cases, traditional balloon dilation required multiple procedures with increased complications.[5]

In these refractory benign biliary stricture patients, cutting balloon technology can be an option. The technology is commonly used in angioplasty. The Cutting balloon has knives on its surface to make incisions. By making micro incisions with the knives, the device effectively dilates the vascular wall with relatively low pressure (Fig. 1). With this strength, a larger cutting balloon has been used in several cases of benign biliary strictures, which are refractory to high-pressure balloon dilations and surgical reconstruction is undesirable.[6,7] Saad et al.[6] used a cutting balloon and subsequently inflated conventional balloon and reported technical success rate of 90% in liver transplant recipients with recurrent strictures. However, there are rare case reports in South Korea. In this study, the cutting balloon dilation was performed in patients with benign bilioenteric anastomotic strictures, refractory, or failure to inflate with a high-pressure balloon. In these cases, we suggest that the cutting balloon can be used in refractory benign biliary stricture patients

CASE

From April 2004 to March 2010, percutaneous biliary balloon dilation with or without percutaneous transhepatic cholangioscopy was performed in 22 patients with benign bilioenteric anastomotic strictures. Among them, four patients met technical failure (Fig. 2). The patients (two men and two women, median age 50.2 years, range 48-67 years) who failed to dilate by using three or fewer sessions of conventional balloon dilatation were included (Table 1). Three patients failed to dilate at primary stricture, and the other

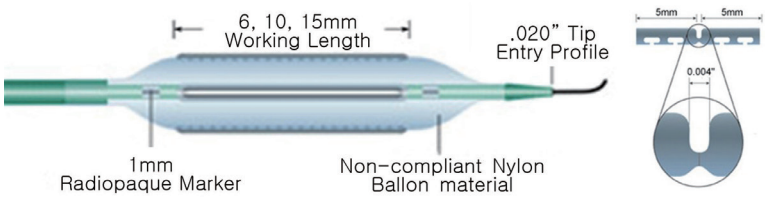

Fig. 1. A picture of cutting balloon.

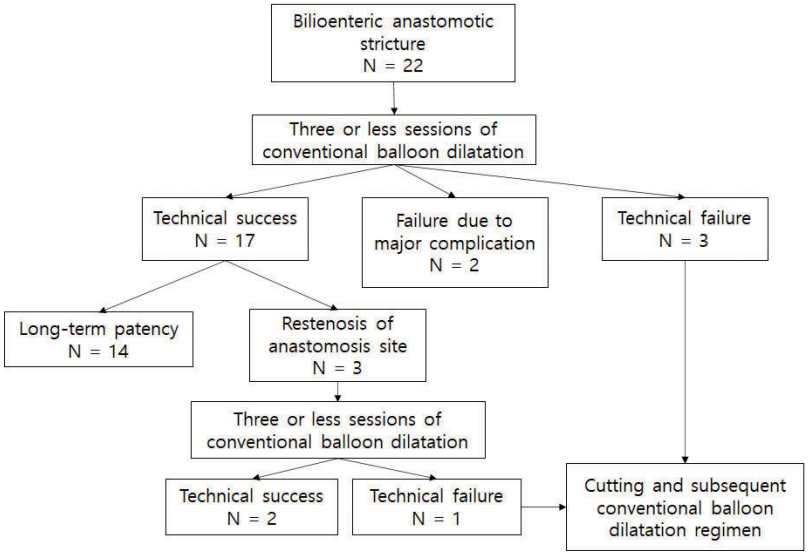

Fig. 2. A flow chart of the patients who were involved in this study.

was at recurrent stricture.

The four patients' common characteristics are as follows: 1) symptoms including fever, right upper quadrant pain, or jaundice; 2) abnormal liver function tests; 3) residual stricture of more than 30% compared to the adjacent normal lumen diameter after more than three sessions of conventional balloon dilation, regardless of whether the stricture recurred or not; and 4) no evidence of malignancy as evaluated by computed tomography, magnetic resonance cholangiopancreatography, bile cytology, or percutaneous transhepatic choledocoscopic biopsy.

The first patient was 38 years old female who got choledochojejunostomy because of benign common bile duct stricture after cholecystectomy. After 11 months of the surgery, she came to the hospital due to stricture on the anastomosis site. Due to the conventional balloon dilatation failure, we used an 8mm cutting balloon and a 12 mm subsequent conventional balloon dilation. Technical success has been achieved and there were no major complications. Duration patency was 39 months.

The second patient was 55 years old male. Due to benign common bile duct stricture after cholecystectomy, he got choledochojejunostomy and stricture occurred at the anastomosis site after 5 months of the surgery. As we failed the conventional balloon dilatation, we used a 6 mm cutting balloon and 10 mm subsequent conventional balloon dilation. There were no major complications and remained patency for 28 months.

The third patient was 60 years old male. He underwent cholecystectomy for gallstones and stricture occurred at the proximal common bile duct after 24 months of the surgery. Conventional balloon dilatation has failed and we used an 8 mm cutting balloon and 10 mm subsequent conventional balloon

Table 1. Clinical features of four patients with refractory benign bilioenteric anastomotic strictures

	Patient 1	Patient 2	Patient 3	Patient 4
Age (years)	38	55	60	51
Gender	Female	Male	Male	Male
Type of surgery	Choledocho-jejunostomy	Hepatico-jejunostomy	Hepatico-jejunostomy	Hepatico-jejunostomy
Time interval between surgery and diagnosis of the stricture	11 months	6 months	24 months	96 months
Cause of surgery	Benign CBD stricture after cholecystectomy	Benign CBD stricture after cholecystectomy	GB stone	GB stone Lt. IHD stone

CBD, common bile duct; GB, gallbladder; IHD, intrahepatic duct.

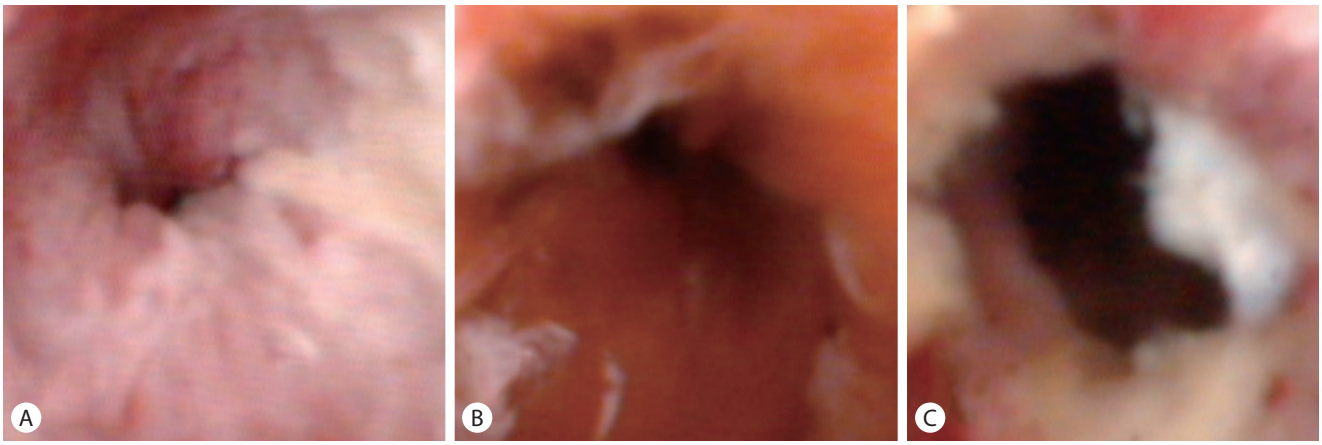

Fig. 3. (A) Cholangioscopic view of tight stricture at hepaticojejunostomy after failure of conventional balloon dilation. (B) Cholangioscopic view after a cutting balloon dilation showing mucosal tearing and minor bleeding. (C) Cholangioscopic view after subsequent larger conventional balloon dilation showing widened lumen.

 https://doi.org/10.15279/kpba.2022.27.3.128

dilation. There were no major complications and the patency was maintained for 10 months.

The fourth patient was 51 years old male. He took cholecystectomy and left lateral liver segmentectomy due to gallstones and left intrahepatic duct stone. When stricture occurred at the proximal common bile duct for the first time, the stricture has been

Table 2. Technical methods and outcomes of four patients with refractory benign bilioenteric anastomotic strictures

	Patient 1	Patient 2	Patient 3	Patient 4
Technical methods				
Diameter of initial cutting balloon	8 mm	6 mm	8 mm	7 mm
Diameter of subsequent conventional balloon	12 mm	10 mm	10 mm	10 mm
Diameter of percutaneous drainage catheter	18 Fr	18 Fr	18 Fr	16 Fr
Outcomes				
Technical success*	Yes	Yes	Yes	Yes
End-treatment success**	Yes	Yes	Yes	Yes
Duration of patency***	39 months	28 months	10 months	9 months
Major complications	none	none	none	none

*Technical success is defined as a residual stricture less than 30% compared to the adjacent normal lumen diameter after balloon dilation regimen.
**End-treatment success is defined as a residual stricture less than 30% compared to the adjacent normal lumen diameter after removal of stents.
***Ductal patency is evaluated by symptoms, liver function tests, and ultrasonography.

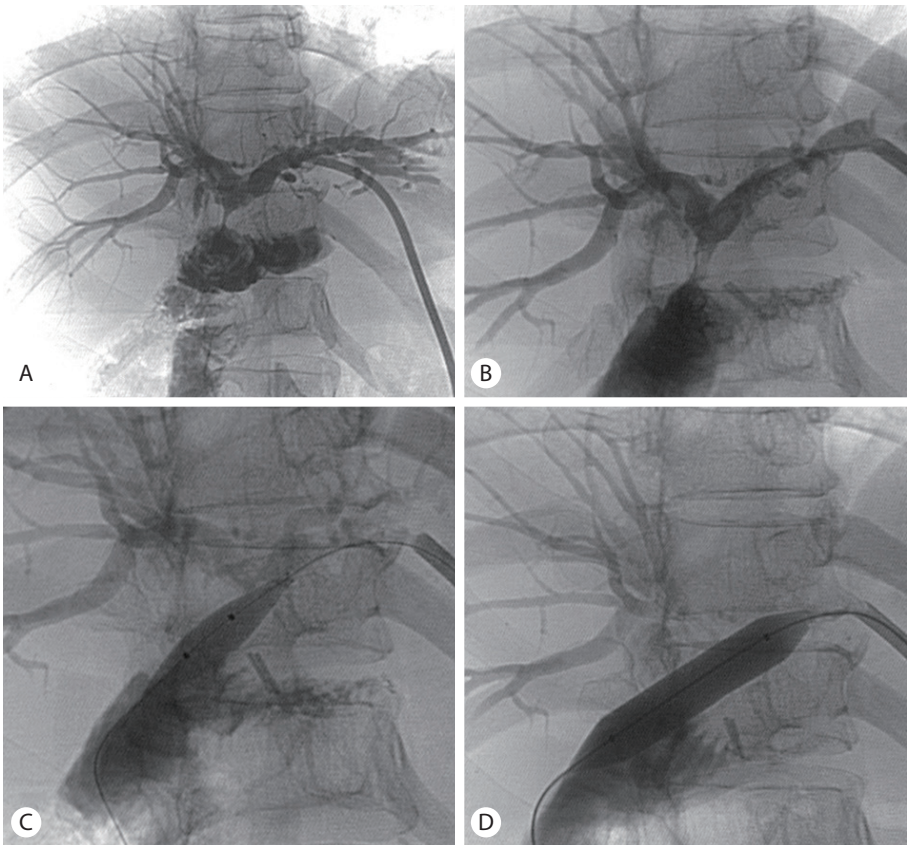

Fig. 4. (A) Cholangiogram showing severe stricture at hepaticojejunostomy. (B) Cholangiogram made after cutting balloon dilation showing satisfactory drainage through the anastomosis. (C, D) A cutting balloon and subsequent larger conventional balloon were adequately dilated.

managed by conventional balloon dilatation. However, after 96 months of the surgery, the stricture recurred and the conventional balloon dilatation has been failed. 7 mm cutting balloon and 10mm subsequent conventional balloon has been used to dilate. There were no major complications and the patency was maintained for 9 months.

After cutting balloon dilations, three to four linear cracks with minor bleeding appeared around the stricture site in all patients (Fig. 3). Cholangiogram performed after subsequent conventional balloon dilation showed an adequate lumen diameter similar to the adjacent normal lumen. All four patients showed technical success without any major complications including bleeding, and bile peritonitis. At end-treatment after placement of the external drainage catheter for 30 days, all patients maintained adequate ductal patency. All patients were followed for 39, 28, 10, and 9 months, respectively (Table 2). Long-term patency was achieved in all patients with symptom-free, normal liver function tests and no bile duct dilation in ultrasound findings.

1. Technical review

All patients received prophylactic antibiotics and intravenous narcotic analgesics. In cases that had failed more than three sessions of conventional balloon dilation, balloon dilation of the stricture with a peripheral cutting balloon (length 1 cm, diameter 6-8 mm) over-the-wire system (Boston Scientific, St. Albans, Herts, UK) was attempted. A cutting balloon is a non-compliant balloon with four atherotomes (i.e. microsurgical blades). When the cutting balloon is inflated, the atherotomes are deployed up to a height of 0.127 mm (0.005 inches) at right angles to each other thereby creating four cracks into adjacent granulation tissue.

A 0.018-inch guide wire was introduced through a percutaneous transhepatic cholangioscopy or an indwelling drain. A minimum sheath (7 Fr) was replaced for the cutting balloon as well as for the subsequent non-compliant balloon (10-12 mm). Initially, the cutting balloon was inflated at 10 atm for 2 minutes, and then, conventional non-compliant balloon dilation was performed. The size of the second balloon (10-12 mm) was always larger than the initial cutting balloon (Fig. 4). The conventional balloon was inflated at up to 15 atm for 1 to 2 minutes. Following the balloon dilation, an external drainage catheter (up to 18 Fr) was inserted through the stricture site. After 2 weeks, cholangiography and a percutaneous transhepatic cholangioscopic biopsy of the stricture site were performed. The indwelling catheter was placed continuously for up to 30 days after balloon dilation and then removed.

Technical success was defined as a residual stricture of less than 30% compared to the adjacent normal lumen diameter after both the cutting and subsequent conventional balloon dilation treatment. End-treatment success was defined as a residual stricture less than 30% at day 30 compared to the adjacent normal lumen diameter after removal of the dilation catheter. Ductal patency was evaluated by symptoms, liver function tests, and ultrasonography every 3 months for 1 year after the balloon dilation, every 6 months for the next 1 year, and every 20 months thereafter. A procedure-related complication was defined as a complication occurring within 30 days after the balloon dilation treatment.

DISCUSSION

Percutaneous conventional balloon dilation with or without placement of an external drain has usually been used to treat benign bilioenteric anastomotic strictures, because surgery has relatively high morbidity and mortality and an endoscopic approach is often impossible due to anatomic inaccessibility.[1,3,5] However, percutaneous balloon dilation is sometimes technically difficult because of a failure of the guide wire or balloon catheter to pass through the stricture site. A dilating catheter has been used to pass through a stricture, but these instruments can be difficult or risky in patients with tortuous ducts. A small-caliber angioplasty balloon can also be used but does not achieve adequate ductal diameter.[8] Furthermore, the results of traditional balloon dilation are unsatisfactory in cases with severe fibrosis around stricture. Multiple long-term stents or self-expandable stents have been reported with variable success rates in cases that need repeated dilation.[9-12] However, none of these methods has been proven to be superior to conventional balloon dilation.

A cutting balloon has a slimmer distal shaft (2.7 Fr) than a conventional balloon (3.5 Fr), permitting it to pass through a

 https://doi.org/10.15279/kpba.2022.27.3.128

stricture site more easily. By performing dilation with a cutting balloon, controlled incisions can be made in the stricture. Subsequently inflation of a conventional balloon with a larger size diameter than the diameter of the initial cutting balloon, the adjacent tissue undergoes more controlled tearing, and the ductal diameter increases. This method that produces a crack around the stricture by using a cutting balloon, allows dilation of strictures more easily and to a larger diameter than can be achieved with the conventional balloon.[7]

In our cases, three to four linear cracks were observed around the stricture site at cholangioscopy after a cutting balloon dilation and a larger ductal diameter was obtained at cholangiogram after subsequent conventional balloon dilation.

As repeated balloon dilation of anastomotic strictures is traumatic and causes in more fibrosis, recurrent strictures may be more refractory to conventional balloon dilation than primary strictures. Therefore, increased formation of fibrous tissue around the stenosis area tends to result in poor treatment outcomes. In our study, three patients presented with refractory strictures after more than two balloon dilation treatments achieved successful dilation of the recurrent strictures by using a cutting balloon. In addition, ductal patency was maintained after the placement of an indwelling catheter for a short duration. A cutting balloon dilation seems to make adequate cracks. The crack tears fibrosis or granulation tissues and does not cause perforation. It shows a short duration of the indwelling catheter due to controlled tearing accelerating wound healing. Postoperative benign biliary stricture degenerated capillary vessels in the submucosa.[13] Incision of a cutting balloon causes a laceration that exposes the blood vessels. After the creation of a controlled incision by a cutting balloon, minor bleeding around strictures leads to vascularization of the bilioenteric anastomosis. This results in a shorter duration in which an indwelling catheter is required.

We were concerned about major complications including bile peritonitis and major bleeding. Minor hemobilia was encountered in all cases, but there were no major complications such as biliary ruptures or major hemobilia as compared to complications seen in previous patients with benign biliary stricture.[5,14] We consider that the blades of cutting balloons are sufficiently small so as not to disrupt the fibrotic tissue, but large enough to break the tissue at the strictures. Achieving an adequate depth of the incision in a cutting balloon dilation decreases the risk of major complications. Unfortunately, this device is suitable only for a percutaneous approach in patients with biliary postoperative strictures because of its shorter working catheter length (137 cm). A cutting balloon also cannot be used for bile ducts larger than 8 mm in diameter because of limited size of balloon.

In conclusion, a combination of a cutting and conventional balloon dilation treatment appears to be an alternative treatment method that may results in better outcomes in patients with bilioenteric anastomotic strictures refractory to a traditional balloon dilation treatment.

요 약

경피적 풍선 확장술은 양성의 장담도 문합성 협착 환자에 외부 담도 배액관을 삽관 혹은 삽관하지 않은 경우 모두에서 좋은 비수술적인 대안 방법이다. 일반적으로 이 방법은 높은 기술적 성공률을 보인다. 하지만, 불응성의 강한 협착에서 시술을 시도할 때는 그 결과가 좋지 않다는 한계점이 있다. 이런 불응성 협착의 경우, 절단 풍선이 또다른 옵션이 될 수 있다. 이 연구에서는 기존의 풍선 확장에 불응성이 있는 양성 장담도 문합 협착을 가진 네 명의 환자에서 절단 풍선 시술을 시행하였다. 환자에게는 절단 풍선을 over-the-wire 시스템으로 팽창시킨 후 기존의 풍선 확장술을 시행하였다. 풍선 확장 치료 후 외부 배액관을 협착 부위를 통해 배치하고 최대 30일까지 유지하였다. 이후, 추적 관찰한 네 명의 환자 모두에서 기술적 및 최종 치료 성공 기준이 달성되었다. 이러한 결과를 바탕으로, 절단 풍선 확장의 사용은 기존의 풍선 확장에 불응성이 있는 양성 장담도 문합성 협착 환자들에게 안전하고 효과적인 치료 방법이 될 수 있을 것으로 보인다.

국문 색인: 절단 풍선; 장담도 문합; 양성 협착; 경피적 풍선 확장술

Conflicts of Interest

The authors have no conflicts to disclose.

ACKNOWLEDGMENTS

This work was supported by clinical research grant from Pusan National University Hospital in 2021.

ORCID

Jonghyun Lee	https://orcid.org/0000-0002-9752-5860
Dong Uk Kim	https://orcid.org/0000-0002-7208-7753
Sung Yong Han	https://orcid.org/0000-0002-0256-9781
Gwang Ha Kim	https://orcid.org/0000-0001-9721-5734
Hyung Il Seo	https://orcid.org/0000-0002-4132-7662
Seung Baek Hong	https://orcid.org/0000-0002-1731-0430
Suk Kim	https://orcid.org/0000-0003-3268-1763
Chang Won Kim	https://orcid.org/0000-0001-7853-5580

REFERENCES

1. Genest JF, Nanos E, Grundfest-Broniatowski S, Vogt D, Hermann RE. Benign biliary strictures: an analytic review (1970 to 1984). Surgery 1986;99:409-413.
2. Pottakkat B, Sikora SS, Kumar A, Saxena R, Kapoor VK. Recurrent bile duct stricture: causes and long-term results of surgical management. J Hepatobiliary Pancreat Surg 2007;14:171-176.
3. Davids PH, Tanka AK, Rauws EA, et al. Benign biliary strictures. Surgery or endoscopy? Ann Surg 1993;217:237-243.
4. De Palma GD, Persico F, Masone S, et al. Endoscopic palliative treatment of the common bile duct at the hepatic hilum. Results in 583 patients treated in a single center over a 10-year period. Minerva Chir 2003;58:175-179.
5. Schumacher B, Othman T, Jansen M, Preiss C, Neuhaus H. Long-term follow-up of percutaneous transhepatic therapy (PTT) in patients with definite benign anastomotic strictures after hepaticojejunostomy. Endoscopy 2001;33:409-415.
6. Saad WE, Davies MG, Saad NE, et al. Transhepatic dilation of anastomotic biliary strictures in liver transplant recipients with use of a combined cutting and conventional balloon protocol: technical safety and efficacy. J Vasc Interv Radiol 2006;17:837-843.
7. Atar E, Bachar GN, Eitan M, Graif F, Neyman H, Belenky A. Peripheral cutting balloon in the management of resistant benign ureteral and biliary strictures: long-term results. Diagn Interv Radiol 2007;13:39-41.
8. Freeman ML, Cass OW, Dailey J. Dilation of high-grade pancreatic and biliary ductal strictures with small-caliber angioplasty balloons. Gastrointest Endosc 2001;54:89-92.
9. Costamagna G, Pandolfi M, Mutignani M, Spada C, Perri V. Long-term results of endoscopic management of postoperative bile duct strictures with increasing numbers of stents. Gastrointest Endosc 2001;54:162-168.
10. Draganov P, Hoffman B, Marsh W, Cotton P, Cunningham J. Long-term outcome in patients with benign biliary strictures treated endoscopically with multiple stents. Gastrointest Endosc 2002;55:680-686.
11. Mahajan A, Ho H, Sauer B, et al. Temporary placement of fully covered self-expandable metal stents in benign biliary strictures: midterm evaluation (with video). Gastrointest Endosc 2009;70:303-309.
12. Tee HP, James MW, Kaffes AJ. Placement of removable metal biliary stent in post-orthotopic liver transplantation anastomotic stricture. World J Gastroenterol 2010;16:3597-3600.
13. Geng ZM, Yao YM, Liu QG, Niu XJ, Liu XG. Mechanism of benign biliary stricture: a morphological and immunohistochemical study. World J Gastroenterol 2005;11:293-295.
14. Born P, Rösch T, Brühl K, et al. Long-term results of endoscopic and percutaneous transhepatic treatment of benign biliary strictures. Endoscopy 1999;31:725-731.